


INTERNATIONAL JOURNAL OF FERTILITY & STERILITY

Volume 9, Supplement 1, Summer 2015

ISSN: 2008-076X
eISSN: 2008-0778



www.ijfs.ir

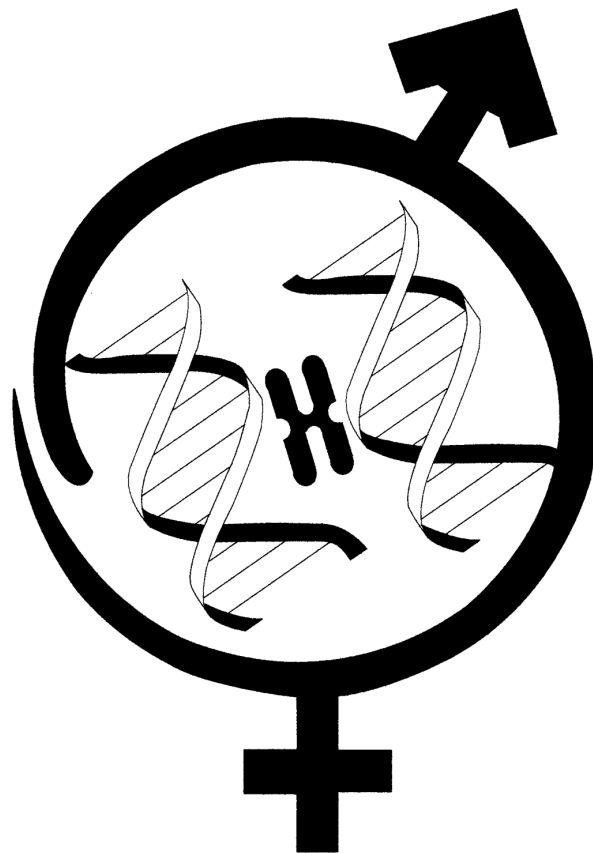


A Quarterly Publication of the Royan Institute

**Abstracts of
Royan International Twin Congress**

**16th Congress on Reproductive Biomedicine
2-4 September 2015**

**10th Seminar on Nursing and Midwifery
2-4 September 2015**



Royan Institute

Reproductive Biomedicine Research Center

Tehran, Islamic Republic of Iran

tor (18%); 36 with endometriosis (21%); 29 with unexplained factor (17%); 8 with uterine immune factor (5%).

Results: Among the 166 cases, 68 patient became pregnant after application of the above therapies. The success rate was 41%.

Conclusion: Because of various limitation, researcher cannot use the standard method for these clinical observation but acupuncture with TCM show cure infertility at a significant rate, and that the treatment provides new hope for those couple

Keywords: Infertility, Acupuncture, Herbal Medicine, Western Medicine

P-95: Seasonal Changes in Hypothalamic Gonadotropin-Inhibitory Hormone Expression in Alectoris Chukar

Mohammadrezazadeh F^{1*}, Jafarzadeh Shirazi MR¹, Zamiri MJ¹, Salehi MS², Namavar MR³, Akhlaghi A¹

1. Department of Animal Science, College of Agriculture, Shiraz University, Shiraz, Iran

2. Department of Animal Physiology, Faculty of Biological Sciences, Shahid Beheshti University, Tehran, Iran

3. Histomorphometry and Stereology Research Center and Department of Anatomical Sciences, School of Medicine, Shiraz University of Medical Sciences, Shiraz, Iran, Email: fmohammadrezazadeh@gmail.com

Background: Gonadotropin-inhibitory hormone (GnIH), initially discovered in birds as a hypothalamic neuropeptide, inhibits the synthesis and release of gonadotropins via affecting GnRH neurons and gonadotropes. Therefore, it could be a key neuropeptide in regulating seasonal breeding in birds. The aim of the present study was to investigate the expression of GnIH in the hypothalamus of male and female chukar partridges during the breeding and non-breeding seasons.

Materials and Methods: In breeding (May) and non-breeding (January) seasons, the brains of male (n=10) and female (n=10) sexually mature chukar partridges were removed following fixation. Sections (30 µm) were prepared from the entire hypothalamus and stained immunohistochemically (GnIH antibody was provided by Prof. K. Tsutsui).

Results: GnIH-immunoreactive (-IR) neurons were primarily found in PVN nucleus and few positive neurons detected in DMN nucleus. The number of GnIH-ir neurons were significantly lower in the breeding season than non-breeding season in both male and female partridges (P<0.05).

Conclusion: The results showed that GnIH neurons may play part in regulating the seasonal breeding in the chukar partridge.

Keywords: GnIH, Partridge, Hypothalamus

P-96: Extensive Fundal Uterine Rupture in Post-resection Bicornuate Uterus in a Term Pregnancy: A Case Report

Moukhah S*, Ahmadi F

Department of Reproductive Imaging, Reproductive Biomedicine Research Center, Royan Institute for Reproduc-

ive Biomedicine, ACECR, Tehran, Iran

Email: so.moukhah@gmail.com

Background: Uterine rupture in a term pregnancy is an adverse and rare event with serious maternal and fetal consequences. The history of uterine septum resection is considered as a risk factor for uterine rupture. Women with such circumstances are thus recommended to be considered as having a high-risk pregnancy. Accordingly, their prenatal care should be implemented in shorter intervals during which more attention should be paid to auscultation of fetal heart rate and warning signs (e.g. hemorrhage and severe and sudden pain). We report a case of asymptomatic fundal uterine rupture in a woman with term pregnancy.

Materials and Methods: Uterine rupture can be caused by various reasons. However, according to previous studies, the most important reason is the history of a previous cesarean scar in a pregnant uterus. In the case we presented at Akbarabadi Hospital, the history of uterine septum resection was the cause of uterus rupture. Incidence of uterus rupture is possible during the whole stage of pregnancy, especially during the labor and due to induction with oxytocin. In our case, asymptomatic uterine rupture was observed in a female with term pregnancy who was not induced with oxytocin. Such a case has never been reported. It should be noted that despite a previous cesarean scar in our case, the uterine fundus was ruptured due to a scar caused by uterine septum resection. Possible causes of such ruptures in previous reported cases included deep resection of myometrium and weakening of the fundus and/or an undiagnosed rupture.

Results: Maternal health care providers should pay more attention to the outcomes of the septum resection itself. They are required to prevent uterine rupture with more accurate control of patients and faster diagnosis of a uterine susceptible to rupture.

Conclusion: Maternal health care providers should pay more attention to the outcomes of the septum resection itself. They are required to prevent uterine rupture with more accurate control of patients and faster diagnosis of a uterine susceptible to rupture.

Keywords: Post-Resection Bicornuate Uterus, Term Pregnancy, Uterine Rupture

P-97: The Effects of Catalase Addition to The Cryopreservation Medium on Follicles Apoptosis and Oxidative Stress in Human

Najafi A^{1*}, Asadi E¹, Raisi Dehkordi Z²

1. Department of Anatomical Sciences, School of Medicine, Tehran University of Medical Sciences, Tehran, Iran

2. Department of Midwifery, School of Midwifery and Nursing, Shahrekord University of Medical Sciences, Shahrekord, Iran

Email: najafi_a@razi.tums.ac.ir

Background: Today, cryopreservation of ovarian tissue has been the effective procedure to restore fertility in can-